

## PROSTHETIC REMEDIATION OF SPEECH QUALITY FOR POST VELUM RADIOTHERAPY USING PHONETIC INVESTIGATION METHOD

Bernard Teston \* and André Besson \*\*

\*Laboratoire Parole et Langage CNRS, Aix-en-Provence, France

\*\* Hôpital Paoli-Calmettes CRAM, Marseille, France

### ABSTRACT

Patients having undergone irradiation in the pharyngeal area often exhibit a lingual-palatal articulatory deficiency in addition to the velar disorder. This paper shows how a simple but carefully made palate cover plate based on phonetic principles can alleviate some of the velar defects by decreasing the severity of the rhinolalia and correcting the tongue-to-palate contacts required for correct articulation.

### INTRODUCTION

The velum of patients having undergone irradiation in the pharyngeal area often has a normal morphology but remains immobilized in the lowered position. The state of the tissues is generally too poor to allow for restorative pharyngovelar surgery. The only remaining remedy for the velar deficit is an artificial palate. However, such a prosthesis is difficult to achieve due to the shape of the velum, which excludes the use of Schilsky-type obturators. Our aim here is to show that, in such cases, a phonetic approach based on the techniques used to investigate speech production, associated with particular care in making the prosthesis, can substantially improve the patient's speech.

### 1. CLINICAL DESCRIPTION OF A CASE

The patient is a 33-year-old woman. At the age of 17, she was diagnosed to suffer from epidermoid carcinoma of the cavum, accompanied by substantial ganglionic extension. Given the severity of the case, chemotherapy was chosen, in conjunction with massive radiation encompassing the entire cavum.

Today the patient is considered to be cured, although the aftereffects of the radiation therapy are great. The main characteristic of the sequels is an overall stiffness of the musculature in the pharyngeal region. The patient reports that

her mouth and pharynx feel as if they "form a single block."

In its atonic state, the velum remains lowered. The upper tongue muscle is altered in an asymmetrical manner, which leads to substantial deviation to the right and a twisted tongue. The left dorsal surface also exhibits a concave type of dysmorphology. The patient's jaw opening at the central incisors is reduced to 18 mm. The patient also suffers from partial asialia and a slight hindrance in swallowing. Her speech is highly affected, with significant rhinolalia accompanied by difficult lingual-alveolar articulation, worsened by incorrect lip dynamics which tend to be used as an offset for her overall pronunciation problems. Her difficulty speaking, broken by frequent breath taking, is a real handicap with which the patient has trouble coping (she is a psychologist in an unemployment office).

As pharyngovelar restorative surgery is not advisable, the maxillofacial surgery ward of the Paoli-Calmettes Hospital referred the patient to our laboratory for potential fitting with a prosthesis.

### 2. PHONETIC DESCRIPTION OF THE CASE

#### 2.1 Assessment of Rhinolalia

The first step was to determine the severity of the patient's rhinolalia and the residual motricity of the velum. This was done using an aerophonometer, a device which provides accurate measurements of the buccal and nasal air flow rates [1]. The aerophonometer was developed for this purpose as part of the EVA system [2]. The evaluation corpus consisted of two sentences which the patient was asked to pronounce several times: "ta toupie va trop vite" /tatupivatrovit/, designed to detect nasal leakage on the consonants "p" and "t", and "ta tante a chanté" /tatâtafâte/, aimed at displaying the movements of the velum via variations in the nasal air flow rate on the

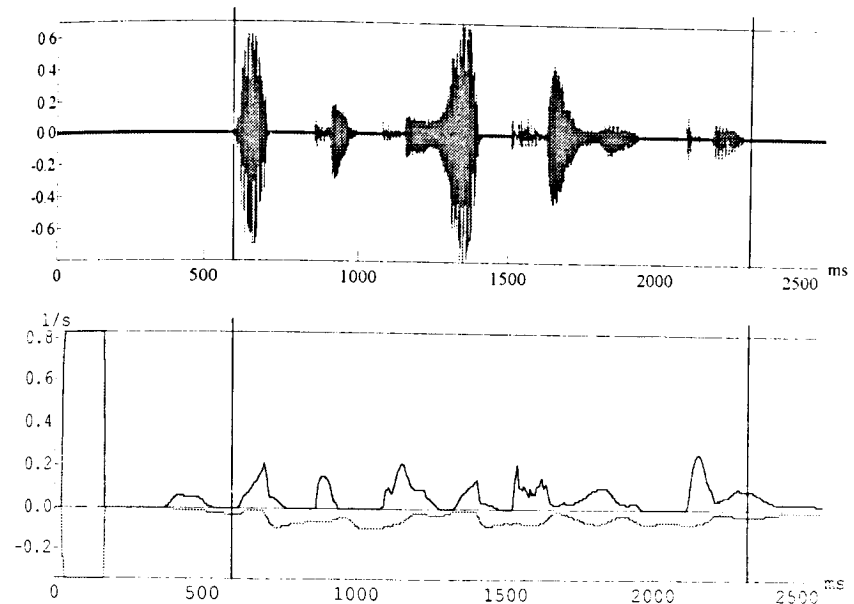


Figure 1: "latupivatrovit" before prosthesis. Upper trace: Spl. Lower trace: oral airflow and inversed nasal airflow

For the ten repetitions of each of the two sentences, the total volume of air exhaled from the nose and mouth were calculated, in addition to the ratio of the nasal air volume to the total volume exhaled. For the first sentence, an average of 51% of the air was exhaled through the nose (for a normal subject, this average is less a few percents).

Figure 1 shows the closest production to the mean for the first sentence. We can see a heavy and nearly constant nasal leakage everywhere except on the nuclei of the vowels "a" and "o", with the maximum occurring on the voiced consonant "v" and the stops "p" and "t". The movement span of the apical-alveolar and labial apparatus is small, the bursts of the consonants "p" and "t" are not very prominent, and the acoustic signal on the voiced consonant "v" is weak. This indicates atonic articulation: the subject "holds back" in order to avoid having to take too many breaths. For the second sentence, nasal leakage is approximately the same (49%) on the closure of the consonants "t" and "ch" in the nasalized environment. The airflow rates for the oral

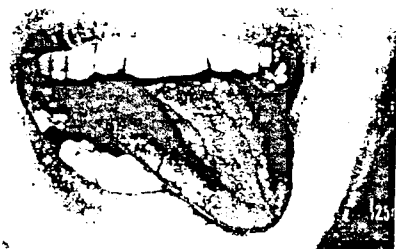and nasal vowels are the same, which confirms the fact that the velum remains immobile and lowered during phonation.

#### 2.2 Palatographic examination


The tongue asymmetry observed clinically was confirmed by palatography [4].

As it was impossible for the subject to open her mouth so that we could photograph her palate, we used an alternative approach which consisted of coating a palate plate and photographing the tongue after articulation. The purpose of this test was to point out the areas of excessive and insufficient contact brought about by the lingual asymmetry.

The consonants tested were "t", "s", and "k" surrounded by the vowel "a". For "ata", the tongue made a horseshoe type of contact, with a narrower area on the left. For "asa", there were two lateral contacts, again with a smaller area on the left. For "aka", the contact was not entirely closed due to the lack of left paramedial contact (figure 2).



[ asa ]



[ asa ]

Figure 2 : asymetry of the lingopalatal contacts

Although this investigation was skewed to some extent by the change in procedure, it nevertheless allowed us to determine what stop consonant compensations were occurring on the inner arch of the palatal plate.

### 3. MAKING THE PALATOVULAR PROTHESIS

The patient's normal but rigid velar morphology prevents the insertion behind the velum of a support for a Schilsky type of pharyngeal obturator. For cases like this, we designed a simple palatovelar cover plate capable of raising the velum and thereby reducing the severity of the rhinolalia. Such a plate should also allow the subject to more evenly distribute tongue contacts in the areas necessary for correct articulation.

Due to the patient's narrow buccal opening, obtaining an imprint of the palate posed an additional problem which was solved by making a custom-designed imprint carrier. Several imprints were made to ensure the quality of the mold, which was then used to make the palatographic plate and several palatal plates in biocryl resin.

The reference plate is 8/10 mm thick, with a sagittal profile that extends the hard palate. Its posterior edge is located 4 mm from the uvula. On this basic plate, a thickened area on the left inner arch is used to correct the defective occlusion caused by the lingual asymmetry. The thickness needed for correction was tested empirically, under continuous palatographic control, until the best trade-off was obtained between "too much and not enough" occlusion.

Three plates were produced from the reference plate (figure 3), each with a gradual increase in the thickness of the arch starting at the beginning of the postdam and ending at an added thickness of 2 mm, 4 mm, and 6 mm, respectively.



inner velopalatal plate



profile velopalatal plate

Figure 3: velopalatal prothesis

### 4. RESULTS OF THE REHABILITATION

The patient felt "supported" and relieved during articulation as soon as she began wearing the 2-mm plate, which she perceived as a prop during continuous speech efforts. Habituation to this 2-mm plate took approximately one month. The 4-mm plate was also worn for one month, after which discomfort was eliminated.

Figure 4 shows the mean nasal air

volume of 32% achieved on the first sentence. This is not a very large gain but allows the subject to take breaths less frequently and to achieve better apical-dental and labial articulation. Stop consonants such as "p" and "t" are more clearly marked, and the signal on the voiced consonant "v" is not as weak. According to individuals in the subject's surroundings,

the patient's speech is more natural and her voice has a more pleasant quality. However, in exchange, the subject can only swallow liquids.

After these first two months, the subject was fitted with the 6-mm plate. She is now capable of making well-articulated speeches in public, without excessive fatigue. A final metal plate was made.

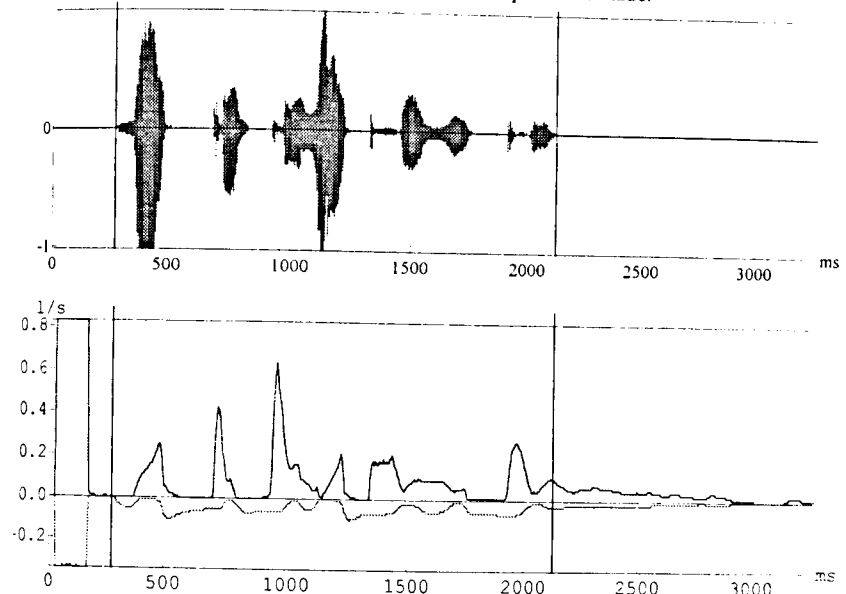


Figure 4: " latupivatrovit " with 4 mm plate prothesis. Upper trace: Spl. Lower trace: oral airflow and inversed nasal airflow

### CONCLUSION

Designing and developing such a prothesis requires sustained efforts on the part of the patient, and careful work and substantial knowledge about the physiological mechanisms of speech production on the part of the specialist. However, the actual fabrication and use of the prothesis are relatively simple and non-traumatic. In the light of these positive results, we consider this method to be an effective solution to speech rehabilitation in difficult cases where restorative surgery is not recommended. The method has been used on other less or equally severe cases, and the results have been just as good.

### REFERENCES

- [1] - Teston B. (1983), "A system for the analysis of the aerodynamic parameters of speech", *10th International Congress of Phonetic Sciences*, Utrecht, Section 5, 457.
- [2] - Teston B. et Galindo B. (1995), "A diagnostic and rehabilitation aid work station for speech and voice pathologies", *Proceedings of Eurospeech 95*, 4 pp.
- [3] Edwards, M. and Watson A.C.H. (1980) *Advances in the management of cleft palate*, Churchill Livingstone, Edinburgh, chap. 16, 232-246.
- [4] Besson, A. (1974), *Incidence de la téléradiographie et de la palatographie en prothèse vélopalatine*, Thèse Medical University, Marseille, 264.